94

TAU PROTEIN AND TAUOPATHY

MAKOTO HIGUCHI
JOHN Q. TROJANOWSKI
VIRGINIA M.-Y. LEE

TAU-POSITIVE FILAMENTOUS LESIONS IN NEURODEGENERATIVE DISEASES

Neurofibrillary Lesions of Alzheimer's Disease Brains

Although the mechanisms underlying the onset and progression of Alzheimer's disease (AD) have not been fully elucidated, the two diagnostic neuropathologies in the AD brain (i.e., amyloid plaques and neurofibrillary lesions) (1, 2) have been implicated mechanistically in the degeneration of the AD brain, and they are considered to be plausible targets for the discovery of potential therapeutic agents to treat this common dementing disorder. AD is a genotypically and phenotypically heterogeneous disease. In spite of this genetic heterogeneity, abundant amyloid plaques and neurofibrillary lesions, including neurofibrillary tangles (NFTs), neuropil threads, and plaque neurites are observed consistently in all forms of AD, and both plaques and tangles are required to establish a definite diagnosis of AD in a patient with dementia.

Amyloid plaques are extracellular deposits of fibrils formed by β-amyloid (Aβ) peptides cleaved from APP, but Aβ also forms diffuse plaques that contain primarily nonfibrillar deposits of Aβ peptides. The neuritic type of amyloid or senile plaque (SP) binds amyloid dyes such as thioflavin-S and Congo red because of the presence of Aβ fibrils with a β-pleated sheet structure. The neurofibrillary AD lesions also contain aggregated filaments, but they are formed by abnormally phosphorylated tau proteins that accumulate as NFTs in neuronal perikarya and as neuropil threads or dystrophic neurites in dendrites and axons. However, NFTs may be released into the extracellular space of the AD brain, following the degeneration of tangle-bearing neurons, and they are referred to as "ghost tangles." Finally, dystrophic neurites are frequently associated with amyloid plaques to form neuritic plaques.

Both amyloid plaques and neurofibrillary lesions are considered to play independent and/or interrelated roles in the mechanisms that underlie the onset and relentless progression of brain degeneration in AD. Indeed, serveral studies have shown that NFTs correlate with the severity of dementia in AD, as do losses of synapses and neurons (10–13). Although there is a poor correlation between these parameters and the concentration or distribution of amyloid deposits (11,13), this could reflect the turnover of these lesions. Furthermore, it has been reported that a small population of AD patients show abundant NFTs but very few amyloid plaques (14), which may signify that there is a causal relationship between the accumulation of NFTs and the clinical manifestations of AD.

Despite heterogeneity in the AD phenotype, the progressive accumulation of NFTs follows a stereotypical pattern as described by Braak and Braak (15), who defined six neuropathologic stages of AD progression determined by the distribution and severity of NFTs. Stage I shows NFTs and neuropil threads confined to pre-α neurons of the transentorhinal cortex, and stage II shows a more remarkable involvement of this area and a mild involvement of the pre-α neurons in the entorhinal cortex. AD brains in stage III show severe neurofibrillary lesions in the above-mentioned regions as well as the emergence of extracellular tangles, and extensive neurofibrillary lesions are found in the deeper layers of entorhinal and transentorhinal cortex in stage IV. Stages III and IV are also characterized by neurofibrillary pathology in layer I of Ammon's horn in the hippocampus and in subcortical nuclei. Finally, increasingly abundant neurofibrillary lesions in isocortical association cortex define stages V and VI.

Neurofibrillary lesions such as NFTs, neuropil threads, and plaque neurites are argyrophilic structures, but they are visualized most effectively using immunohistochemistry and antibodies to phosphorylated tau proteins. In addition to neurofibrillary tau lesions, some neurons show diffuse perikaryal tau immunoreactivity, and this so-called "pretan-

Makoto Higuchi, John Q. Trojanowski, and Virginia M.-Y. Lee: Department of Pathology and Laboratory Medicine, University of Pennsylvania, Philadelphia, Pennsylvania

gle" tau pathology is not stained by amyloid dyes such as thioflavin-S and Congo red, unlike NFTs and other neurofibrillary lesions. Thus, "pretangle" tau pathology may be an early stage in the formation of NFTs prior to the accumulation of abnormal tau filaments.

Tauopathies Other than AD

Neurofibrillary lesions that are positive for thioflavin-S, silver stains, and anti-tau antibodies are also observed as the predominant brain pathology in a group of neurodegenerative disorders other than AD, which are now categorized as tauopathies (Table 94.1). Some of these diseases also show the abundant coexistence of amyloid plaques. For example, neurofibrillary lesions coexist with Aβ deposits in AD as well as in Down syndrome (16,17), dementia pugilistica (18), and inclusion-body myositis (19–21). Further, in some cases of Gerstmann-Sträussler-Scheinker disease (GSS) (22,23), Creutzfeldt-Jakob disease (24), and prion protein cerebral amyloid angiopathy (25), neurofibrillary lesions coexist with prion protein amyloid deposits. On the other hand, amyotrophic lateral sclerosis/parkinsonism-dementia complex (ALS/PDC) found in the Chamorro inhabitants of Guam and Rota in the Mariana Islands shows abundant NFTs but very few amyloid plaques (26–29). Moreover, neurofibrillary lesions without amyloid plaques are observed in argyrophilic grain dementia (30,31), Pick disease (32–34), corticobasal degeneration (CBD) (35–38), progressive supranuclear palsy (PSP) (39–41), multiple system atrophy (MSA) (42), Niemann-Pick disease type C (43–45), diffuse neurofibrillary tangles with calcification (46), Hallervorden-Spatz disease (47), subacute sclerosing panencephalitis (48), and frontotemporal dementia and parkinsonism linked to chromosome 17 (FTDP-17) (49,50). However, some of these disorders, such as MSA, various subtypes of AD, Hallervorden-Spatz disease, and so on also have prominent synuclein brain lesions.

The tau pathology of AD is almost limited to neurons, whereas some other tauopathies exhibit both neuronal and glial tau inclusions. Brains of MSA, CBD, PSP, and FTDP-17 contain abundant tau deposits in astrocytes as well as oligodendrocytes (50–61). On the other hand, in familial multiple system tauopathy with presenile dementia (MSTD), affected glial cells are primarily oligodendrocytes (62–64).

TABLE 94.1. DISEASES WITH TAU-POSITIVE NEUROFIBRILLARY LESIONS

Diseases showing coexistence of tau and amyloid pathologies
Alzheimer's disease
Creutzfeldt-Jakob disease
Dementia pugilistica
Down's syndrome
Gerstmann-Sträussler-Scheinker disease
Inclusion-body myositis
Prion protein cerebral amyloid angiopathy
Diseases without distinct amyloid pathology
Amyotrophic lateral sclerosis/parkinsonism–dementia complex
Argyrophilic grain dementia
Corticobasal degeneration
Diffuse neurofibrillary tangles with calcification
Frontotemporal dementia with parkinsonism linked to chromosome 17
Hallevorden–Spatz disease[a]
Multiple system atrophy[a]
Niemann–Pick disease, type C
Pick's disease
Progressive subcortical gliosis
Progressive supranuclear palsy
Subacute sclerosing panencephalitis
Tangle-predominant Alzheimer's disease

[a]Diseases in which synuclein-positive lesions are the most prominent neuropathologic feature.

Neurofibrillary Lesions with Aging

Abundant amyloid plaques indistinguishable from those in AD brains have been demonstrated in the brains of elderly individuals who are not cognitively impaired (12,65,66); this indicates that accumulation of amyloid plaques alone is not sufficient to cause dementia. Moreover, nondemented elderly individuals also show sparse neurofibrillary lesions with increasing age, but this occurs in limited brain regions (67). Although extensive analysis by Braak and Braak has suggested that neurofibrillary changes of Braak and Braak stage I/II in elderly people may represent early stages of AD pathology (68), this has yet to be proven in studies of subjects who have been subjected to longitudinal cognitive testing up until the time of death.

Significances of Tau Pathology in Neurodegenerative Disorders

Aggregation of tau into neurofibrillary lesions is a neuropathologic hallmark of many neurodegenerative diseases, and these tauopathies can be subclassified with regard to coexisting amyloid or other brain pathology, the affected cell types and the affected CNS areas. Coexistence of tau and amyloid pathologies in some diseases suggests an interaction between tau and amyloid in mechanisms of brain degeneration. The presence of tau lesions in the brain without amyloid plaques in other tauopathies indicates that these neurofibrillary lesions are not mere consequences of neurotoxicity owing to amyloid deposits, but are direct causes of neurodegeneration. Although it is likely that the diversity of affected cell types and/or CNS regions in tauopathies will be explained more fully based on mechanistic relationships between genetic and biochemical differences among these cells, brain regions, and diseases, the clinicopathologic, biochemical, and genetic aspects of these disorders so far remain unsettled.

Ultrastructure of Filamentous Tau Lesions

According to transmission electron microscopic (EM) and immuno-EM analyses of tau filaments in various neurofibrillary lesions, the filamentous lesions consist of three types of morphologies. Approximately 95% of the neurofibrillary components in AD NFTs are paired helical filaments (PHFs), and the rest consists of straight filaments (SFs) (69, 70). PHFs have a helical structure consisting of two ribbon-like strands that are paired together in filaments that have a diameter of 8 to 20 nm and a stereotypical periodicity of 80 nm (70,71). In Down syndrome, ALS/PDC, prion diseases with tangles, dementia with tangles only, Niemann-Pick disease type C, and the Seattle family A FTDP-17 kindred with the V337M tau gene mutation, the filamentous tau pathology is composed of fibrils that are ultrastructurally indistinguishable from the PHFs in AD tangles (29, 43–45,70,72,73). Moreover, PSP and Pick disease show tangles composed of numerous SFs and smaller numbers of twisted tau filaments similar to PHFs (63,74). Twisted ribbon-like tau filaments that are morphologically different from AD PHFs and SFs are found in the tangles of the familial MSTD FTDP-17 syndrome caused by a G to A mutation in the intron following exon 10 of the tau gene (64), Dutch family 1 FTDP-17 syndrome owing to the P301L mutation in exon 10 of the tau gene (75), and CBD (76). Unlike AD PHFs, these filaments have an irregular periodicity of 90 to 130 nm (64).

Nonetheless, immuno-EM studies have demonstrated that all the filamentous structures in the tangles of all of these tauopathies are composed of aberrantly hyperphosphorylated tau proteins, and possess the same tau epitopes (77–82), although the relative abundance of different pathologic tau isoforms may vary in these tauopathies, as discussed in the following. Currently, there seems to be no association between ultrastructural diversity and biochemical or genetic property in tauopathies. Observation of hybrid filaments suggests a transition from PHF to SF.

BIOCHEMICAL FEATURES OF TAU PROTEINS IN NORMAL AND PATHOLOGIC CONDITIONS

Localization and Function of Tau Protein

Tau is a low molecular weight component of cytoskeletal structures and is known as one of the microtubule-associated proteins (MAPs). Neuronal MAPs consisting of tau and MAP2 regulate the assembly of microtubules (MTs). Although tau and MAP2 are thought to have similar functions, intracellular localization of tau largely differs from that of MAP2. The mRNAs encoding tau proteins are expressed predominantly in neurons, where these tau proteins are localized mostly to axons of the CNS and PNS under normal physiologic conditions (83,84), whereas the neurofibrillary lesions in AD accumulate in the neuronal perikarya, axons, and dendrites. In contrast to the axon-specific distribution of tau in normal states, MAP2 has somatodendritic localization (85,86). Although it is likely that the compartment specificity of normal tau and MAP2 in neurons may subserve functional differences such as organization of neuronal polarity and spacing of intermicrotubule distances, or other aspects of axonal and somatodendritic MT distribution and architecture (87–91), there is no direct evidence for these different roles for tau and MAP2. Lower expression of tau mRNA and less abundant tau protein have been observed in astrocytes as well as in oligodendrocytes (92,93), and this suggests that the formation of glial tau inclusions in several neurodegenerative tauopathies results from the aggregation of tau proteins produced in glial cells themselves.

It has been shown in a number of studies from many laboratories that tau proteins play a major role in regulating neuronal MT assembly and stability (94–96). For example, tau proteins promote the polymerization of tubulin into MTs (97), and tau bound to MTs help stabilize these structures in the polymerized state (98). Moreover, developing neurons treated with antisense oligonucleotides to tau mRNA to block expression of tau fail to extend axon-like processes, suggesting that tau protein also functions in, or is required for, the establishment of neuronal polarity during development (99,100). However, mice lacking tau protein present no major phenotypic changes initially, and the only abnormal findings in these mice are decreased MT density and stability in some small-caliber axons (101), but they show motor impairments with age (102). Tau is likely to play an essential role in the development of neurons and even glial cells, but it is also probable that other proteins such as MAP1A can be upregulated to partially compensate for the loss of tau at least early in life, as indicated in the preceding tau-knockout mouse study (101,102).

Expression of Multiple Tau Isoforms

As a consequence of alternative mRNA splicing, the single tau gene on the long arm of chromosome 17 gives rise to six brain tau proteins that are normally expressed in the adult human CNS (77,103–105) (Fig. 94.1). The differences among these six brain tau isoforms result from the presence of three (3R tau) or four (4R tau) imperfect MT binding repeats of 31 or 32 amino acids in the carboxy-terminal half of each of two sets of these proteins, as well as from the presence of inserts of 29 or 58 amino acids or no insert at all in the amino-terminal region (77,103). The tandem repeats in the carboxy-terminal half are encoded by exons 9, 10, 11, and 12, and the alternative splicing of exon 10 (E10) results in the generation of E10+ 4R tau and E10− 3R tau mRNAs and their corresponding 4R and 3R tau isoforms, respectively. This consecutive repeat region

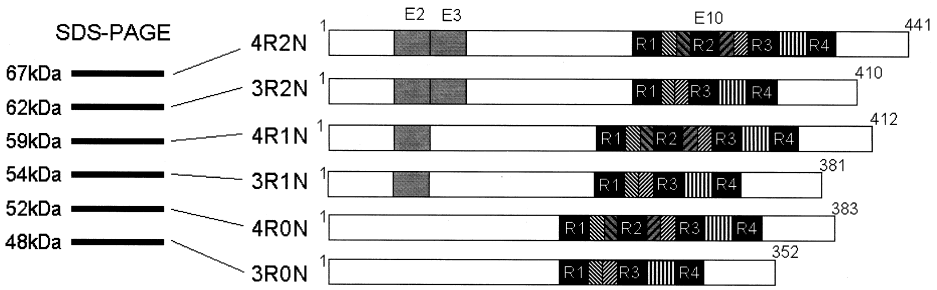

FIGURE 94.1. Six human CNS tau isoforms produced by alternative splicing of the tau gene. The differences among the six isoforms are the number of MT-binding repeat domains *(black boxes)* and the number of amino-terminal inserts. The alternatively spliced exons, exons 2 (E2), 3 (E3), and 10 (E10) are indicated with gray boxes, and hatched boxes indicate the inter-repeat sequences. The recombinant tau proteins run as six bands on SDS-PAGE *(left)*.

constitutes the MT-binding domain of each tau protein (106,107). In each domain, binding affinity to MTs is provided by a binding element that consists of 18 amino acids (107), but the remainder of this motif, known as the interrepeat sequence, also may contribute to the binding of tau to MTs. Indeed, the interrepeat sequence between MT-binding repeats 1 and 2, which is included only in 4R tau isoforms, has a binding affinity for MTs that is more than twofold higher than any MT-binding repeat (108). This may suggests that 4R tau plays a much greater role in regulating the MT-binding than 3R tau, and it is possible that 3R and 4R tau have different MT-binding sites on MTs. The function of the amino-terminal region remains unsettled, but this region is supposed to affect inter-MT distances by forming a bridge between two adjacent MTs. In the PNS, a high molecular weight tau isoform (110 kDa) with one additional exon (exon 4A) is expressed (known as "big tau") (84,110).

The alternative splicing of the six brain tau isoforms is developmentally regulated, and only the shortest tau isoform with three repeats and no amino-terminal inserts (i.e. "fetal tau" or 3R0N tau) is present in fetal human brains (102). By analyzing fresh biopsy-derived nomal fragments of human adult brain, it has been demonstrated that the adult CNS contains the following tau isoforms: tau with one amino-terminal insert (1N tau, 50%), tau with no amino-terminal insert (0N tau, 40%) and tau with two amino-terminal inserts (2N tau, 10%) in order of abundance. In the same analysis, the ratio between 4R and 3R tau isoforms has been found to be approximately 1 (111). However, it also is known that the isoform composition of tau protein differs among species. For example, only the three 4R tau isoforms are known to be expressed in the adult rodent brain, while a 3R0N or fetal tau isoform is expressed in the developing CNS of rodents (112). Although the reasons for this difference between the adult rodent and human brains are not known nor is the functional consequence thereof evident at this time, it is possible that the lack of a stem-loop structure in the intron following E10 in rodents versus humans may account for the failure to express 3R tau isoforms in the adult rodent brain.

Phosphorylation of Tau in Normal and AD Brains

Tau is a phosphoprotein, and tau isolated from the developing and adult brain is phosphorylated at multiple sites. PHF-tau extracted from the AD brain shows three major bands (approximately 60, 64, and 68 kDa) and one minor band (approximately 72 kDa) in SDS-PAGE. Enzymatic dephosphorylation of PHF-tau *in vitro* using alkaline phosphatase changes the electrophoretic mobility of these three bands to generate six bands that are identical to the six tau isoforms extracted from normal human brain after dephosphorylation and the six recombinant human tau proteins. This suggests that PHF-tau in AD is composed of all six tau isoforms that are abnormally phosphorylated. Indeed, these PHF-tau bands are detected using antibodies specific for phosphorylated tau epitopes as well as by other phosphorylation-independent anti-tau antibodies.

Approximately 20 serine and threonine residues in tau, some of which are followed by a proline, currently are known to be sites of normal phosphorylation (113,114) (Fig. 94.2). Although many of these sites initially were thought to be unique to PHF-tau in AD (114), subsequent studies summarized in the following did not confirm this. Most of these phosphorylation sites are clustered in regions flanking the MT-binding domains, and thus it is presumed that the phosphorylation of these sites influences the binding of tau to MTs. In fact, the conformation of tau is changed by phosphorylation (115), and this reduces binding of tau to MTs (98,116–119), lowers the ability of tau to promote MT assembly (120) and decreases the stability of MTs (121,122). It has also been shown that PHF-tau cannot bind to MTs (117,118), and that the binding ability is restored after enzymatic dephosphorylation of PHF-tau *in vitro* by phosphatase (118,123,124). If phosphorylation of a certain site is unique to PHF-tau in AD, elucidation of the mechanism for phosphorylation of such a site could provide much information on the pathogenesis of AD. However, the phosphorylation at multiple sites on tau is considered to be requisite for eliminating the MT-binding ability of PHF-tau (125). In addition, normal human fetal tau is more phosphorylated than tau proteins extracted from

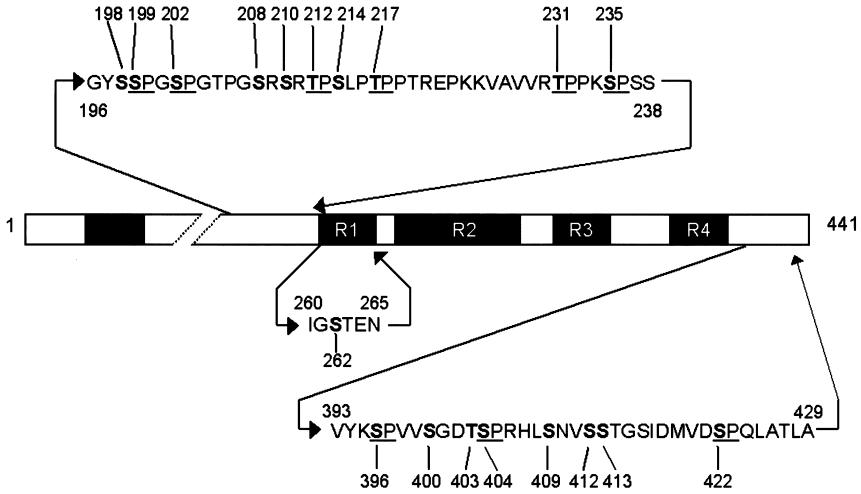

FIGURE 94.2. Phosphorylation sites identified in human PHF-tau. The numbers are based on those in the longest isoform with 441 amino acid residues. The proline-oriented sites are indicated with underlines.

postmortem normal adult brain, but almost all of the phosphorylated sites in normal fetal tau are identical to those in PHF-tau (114,117,126), and it is known that fetal tau also is less capable of binding to MTs than normal adult tau (117). Furthermore, normal adult human tau isolated from biopsy-derived brain sample is phosphorylated at most of the known phosphorylation sites in PHF-tau, albeit to a much lesser extent (127,128). Nevertheless, there still remains a possibility that the difference between PHF-tau and normal tau is not only the extent of phosphorylation, but also the aberrant phosphorylation of some sites that are unique to PHF-tau. In fact, serine212 and serine214, the two phosphorylated residues contained in the epitope that are required for recognition by the anti-phospho-tau antibody AT100/AT10 (129,130), are at least two abnormally phosphorylated sites that are known to be unique to PHF-tau (128). This antibody fails to recognize tau isolated from fetal and biopsy-derived normal adult human brain (128), and thus phosphorylation of Ser212/Ser214 appears to be highly specific to PHF-tau in AD, but these sites also may be phosphorylated in the abnormal tau proteins in other tauopathies. Therefore, PHF-tau is likely to be "hyperphosphorylated" (i.e., phosphorylated to a greater extent) as well as "aberrantly phosphorylated" (i.e., phosphorylated at unique sites).

The extent of tau phosphorylation is regulated by the activities of phosphatases and kinases. Therefore, increased activities of kinases and/or decreased activities of phosphatases could presumably lead to the hyperphosphorylation of tau, thereby resulting in the formation of PHF-tau. Although several different kinases have been demonstrated to be capable of phosphorylating tau *in vitro,* the specific kinases that are responsible for the phosphorylation of tau in the living human CNS remain to be identified. Only two kinases, glycogen synthase kinase-3β (GSK-3β) and cyclin-dependent kinase 5 (Cdk5), have been copurified with MTs (131,132). GSK-3 is known to phosphorylate endogenous tau expressed in neurons (133), and it is abundant in the brain (134). Cdk5 is normally activated by a regulatory protein p35 (135). Cdk5 is supposed to be active in neurons because p35 is expressed primarily in neurons (135,136). However, a recent study has shown that a truncated form of p35 (known as p25) accumulates in neurons of the AD brain, and that p25 binds to Cdk5, leading to a deregulation of this kinase (137). Accordingly, hyperactivated Cdk5 may be caused by accumulation of p25, and this may be part of the mechanism that causes the hyperphosphorylation of tau in AD.

Among many phosphatases, protein phosphatase 2A (PP2A) and 2B (PP2B or calcineurin) have been shown to be enzymatically active in biopsy-derived human brain tissue, and *in vitro* studies have shown that these enzymes dephosphorylate several phospho-serine and phospho-threonine residues in tau (70,124,128,129,139,140). Thus, these phosphatases may be involved in the generation of PHF-tau, but there has been no evidence for decreased phosphatase activity in the AD brain, and thus roles played by these enzymes in formation of PHF-tau are still to be elucidated. Nonetheless, a recent study has demonstrated reduced PP2A subunit mRNAs in the AD hippocampus when NFTs are abundant, so it is plausible that this might contribute to mechanisms underlying PHF-tau formation in AD (140a).

Other Tauopathies

Immunoblot analyses of brains from patients with tauopathies other than AD have demonstrated that insoluble tau fractions are detectable using many different phosphorylation-dependent antibodies to epitopes spanning the tau molecule, suggesting that the filamentous inclusions in these diseases are composed of hyperphosphorylated tau similar

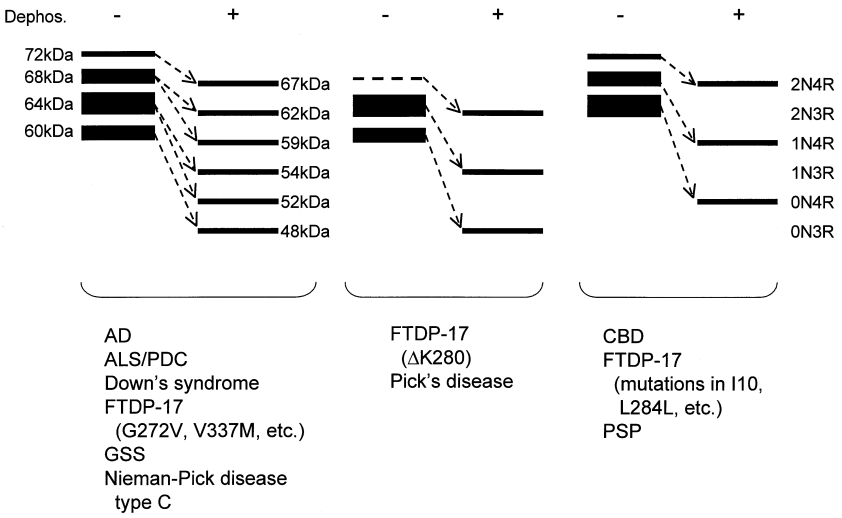

FIGURE 94.3. Schematic representation of sarkosyl-insoluble tau bands from different tauopathies before (−) and after (+) dephosphorylation. The insoluble tau composed of all six isoforms shows three major bands (60, 64, and 68 kDa) and one minor band (72 kDa) before dephosphorylation. In some tauopathies, 3R tau isoforms are major components of the insoluble fraction, running as two major bands (60 and 64 kDa) and one minor band (68 kDa). Tauopathies with insoluble tau consisting of 4R tau isoforms shows two major bands (64 and 68 kDa) and one minor band (72 kDa).

to PHF-tau in AD. Three types of abnormal tau isoform profiles have been found in tauopathies other than AD (Fig. 94.3). For example, similar to AD, three predominant PHF-tau–like bands of 60, 64, and 68 kDa and one minor band of 72 kDa are observed in Down syndrome, GSS disease, ALS/PDC of Guam, Niemann-Pick disease type C, and some FTDP-17 kindreds caused by certain tau mutations (17,23,29,43,72). These bands have been shown to contain all six tau isoforms in several studies. On the other hand, biochemical analyses of Pick disease have shown a characteristic pattern of tau isoform composition consisting of two major tau bands of 60 and 64 kDa and one minor tau band of 68 kDa (34,141). In some studies, these bands are not positive for anti-phospho-tau antibody 12E8, which recognizes an epitope in E10, but our study demonstrated weak but specific recognition (34). Further, several studies have indicated that these bands include only 3R tau isoforms (142,143). The third type of abnormal tau isoform profile is found in CBD (40,76), PSP (41), and some FTDP-17 kindreds with specific tau gene mutations (64,144), and this profile is characterized by two major tau bands of 64 and 68 kDa as well as one minor tau band of 72 kDa. Notably, several studies have indicated that these tau bands predominantly consist of 4R tau isoforms (64,110,144, 145).

FRONTOTEMPORAL DEMENTIA WITH PARKINSONISM LINKED TO CHROMOSOME 17: CAUSED BY MULTIPLE EXONIC AND INTRONIC TAU GENE MUTATIONS

FTDP-17 is a group of familial neurodegenerative tauopathies characterized by diverse but overlapping clinical and neuropathologic features (50,60,146). According to several reports on clinical and neuropathologic features of FTDP-17, three major clinical syndromes have been delineated, and albeit preliminary, they include: disinhibition-dementia-parkinsonism-amyotrophy complex (DDPAC) (55, 147), pallido-ponto-nigral degeneration (PPND) (148), and MSTD (64). However, it is important to note that more than 20 kindreds caused by diverse tau gene muations and variably characterized phenotypes have been reported so far (50). Clinical characteristics of these FTDP-17 tauopathies variably include memory and language impairments, behavioral and psychiatric abnormalities, extrapyramidal signs, and motor deficits (50), each of which presumably reflects differential degeneration of specific brain regions. However, all FTDP-17 brains from affected patients share a common neuropathology characterized by abundant neuronal and to a lesser extent glial fibrillary lesions composed of hyperphosphorylated tau proteins associated with a remarkable loss of neurons in affected regions (144,149–151).

Autosomal dominant inheritance of these FTDP-17 syndromes suggested that one or more genetic mutations might be pathogenic for these disorders, and linkage analyses showed cosegregation of disease with a genetic locus on chromosome 17q21-22 (49,50,60,146,152,153). Because the pathologic hallmarks of these disorders are tau lesions and the tau gene resides within the disease locus of chromosome 17, the tau gene was an obvious candidate for pathogenic mutations in FTDP-17 kindreds. Thus, as expected, several research groups discovered multiple tau gene mutations in 1998, and these mutations were found to segregate with FTDP-17 patients, but they were not seen in normal individuals (151,154,155). Further studies have identified at least 20 distinct pathogenic mutations in exons and introns of the tau gene in many FTDP-17 kindreds, many of which were identified for the first time with the identification of a tau gene mutation. Approximately 10 missense mutations were found in exons of the tau gene, and they include K257T, I260V (Hutton M, personal communica-

tion), and G272V (154) in exon 9; N279K (142), P301L (142,152,155), P301S (156,157), and S305N (158,159) in E10; V337M (155) in exon 12; and G389R (160) and R406W (154) in exon 13 (numbered according to the longest CNS tau isoform consisting of 441 amino acids). Moreover, two silent mutations have been reported, including L284L (159) and S305S (161) in E10 and a mutation resulting in the deletion of single amino acid ΔK280 (159,167) in E10. On the other hand, intronic tau gene mutations in FTDP-17 kindreds are clustered around the 5′ splice site in the intron following E10. They contain E10 + 3 (151), E10 + 12 (163), E10 + 13 (164), E10 + 14 (145,164), E10 + 16 (164,165), and E10 + 33 (162). The currently known tau gene mutations in FTDP-17 kindreds are listed in Table 94.2 and are depicted schematically in Fig. 94.4. The increasing number of tau gene mutations that continue to be identified suggests that FTDP-17 is likely to be more frequent than previously recognized.

In FTDP-17, pathogenic mutations in the tau gene may be pathogenic by one or more abnormalities in tau proteins, and at present, two mechanisms have been proposed to mediate the effects of these mutations based on recent molecular and biochemical analyses (111,154,159,166). The first mechanism involves perturbations of the alternative splicing of E10 by mutations in E10 or around the 5′ splice site in the intron following E10, thereby resulting in an altered ratio of 4R tau to 3R tau proteins. The second pathogenic mechanism directly impairs the ability of tau to bind to MTs and to promote the polymerization and stability of MTs.

The ratio of 4R tau to 3R tau isoforms is approximately 1 in the normal adult human brain, but an increase in the 4R/3R ratio of brain tau isoforms has been demonstrated in brains of FTDP-17 patients with mutations clustered around the 5′ splice site in the intron following E10 and with E10 tau gene mutations including: N279K, L284L, S305N, and S305S (111,154,159). The altered splicing of E10 caused by these mutations results in increased levels of E10+ tau mRNA in FTDP-17 brains presumably owing to greater E10 usage of the E10 5′ splice site as demonstrated by exon-trapping experiments (154,159). Biochemical analyses of tau extracted from autopsied brain samples of patients with PPND (N279K), DDPAC (E10 + 14) and MSTD (E10 + 3) have shown a predominance of 4R tau isoforms (111,145,151). It has been suggested that these mutations affect multiple cis-acting elements that enhance or suppress the usage of 5′ splice site of E10 (151,154,159). A stem-loop structure consisting of sequences around the 5′ splice site in the intron following E10 is thought to inhibit the splicing of E10 presumably by blocking the association of snRNA with the splice site (151,154). Accordingly, it is postulated that these intronic mutations and the exonic mutations S305N and S305S may cause a disruption of this stem-loop structure (154). The S305N mutation has also been suggested to increase the strength of the 5′ splice site (167). However, the S305S mutation, which increases the 4R/3R ratio like the S305N mutation, has been demonstrated to weaken the 5′ splice site (161). Another potential regulatory element might be an exon-splicing enhancer (ESE) or exon-splicing silencer (ESS) element within E10 adjucent to the following intron (159). The N279K mutation is thought to augment the ESE and consequently cause an increase in the 4R/3R ratio of tau isoforms because of the fact that it raises the purine content of this purine-rich domain (i.e., by changing TAAGAA to GAAGAA) (168–171). This mechanistic hypothesis is supported by the observation that the ΔK280 mutation, which produces a deletion of the three adjacent purines (AAG), abolishes the splicing of E10 into tau mRNAs (159). The silent mutation L284L is likely to disturb the ESS (159), but it also is possible that this mutation augments the effects of the ESE.

The binding sites on MTs for 4R tau and 3R tau isoforms have been suggested to be different (109), and increases in the 4R/3R tau isoform ratio is likely to produce an excess

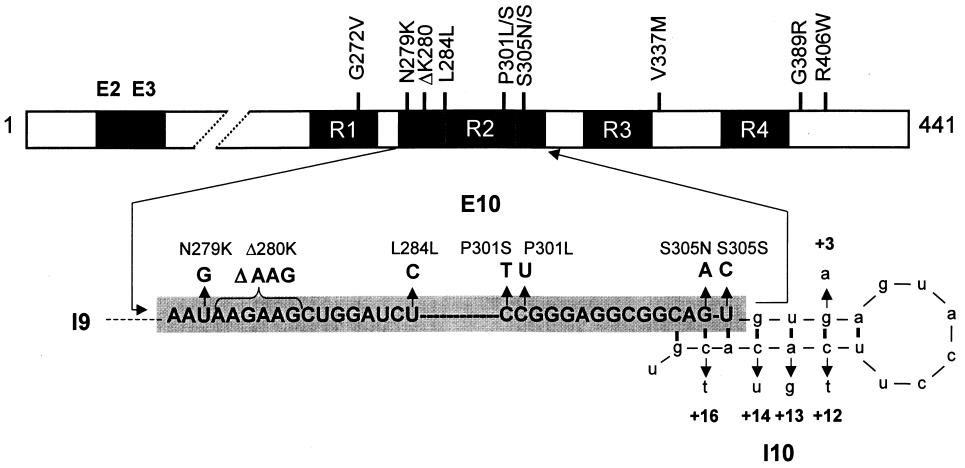

FIGURE 94.4. Mutations identified on tau gene in FTDP-17. The mutation sites are depicted on the longest tau isoform. The alternatively spliced inserts are indicated as gray boxes and MT-binding repeats are shown as black boxes. Sequences in intron 10, which form a stem-loop structure, are presented in lower case.

TABLE 94.2. MUTATIONS ON THE TAU GENE FOUND IN FTDP-17

Mutation	Location (Domain)	Effects on Exon 10 Splicing	Predominant Tau Isoforms	Effects on MT Binding	Disease/Syndrome	Tau-Positive Neuropathology	References
K257T	E9 (R1)	N/A	N/A	N/A	N/A	Tau as well as Pick body-like inclusions	[a]
I260V	E9 (R1)	N/A	N/A	N/A	N/A	N/A	[a]
G272V	E9 (R1)	None	All isoforms	Reduced	HFTD2; "familial Pick's disease"	Inclusions in cortical and subcortical areas	154
N279K	E10 (IR1–2)	Increased	Mainly 4R	None	PPND	Neuronal and glial fibrillary tangles	142
ΔK280	E10 (IR1–2)	Reduced	3R	Reduced	Dutch FTD	N/A	159, 167
L284L (CTT to CTC)	E10 (IR1–2)	Increased	4R	None	"Variant FTD"	Widespread amyloid as well as tau deposits	159
P301L	E10 (R2)	None	All isoforms	Reduced	HFTD1; "Dutch family"	Glial and neuronal tangles	142, 152, 155
P301S	E10, R2	None	All isoforms	Reduced	FTD and CBD-like	Extensive filamentous pathology	156, 157
S305N	E10 (IR2–3)	Increased	Mainly 4R	None	Very early onset presenile dementia, CBD-like	Glial and neuronal inclusions; many unusual ring-shaped NFTs	158, 159
S305S	E10 (IR2–3)	Increased	Mainly 4R	None	PSP-like	Subcortical NFTs	161
V337M	E12 (IR3–4)	None	All isoforms	Reduced	"Seattle family A"	NFTs indistinguishable from AD NFTs	155
G389R	E13 (C-term)	None	All isoforms	Reduced	N/A	Tau as well as Pick body-like inclusions	160
R406W	E13 (C-term)	None	All isoforms	Reduced	"Iowa family," PSP-like	Cortical and subcortical NFTs	154
E10+3 (G to A)	I10 (5′ splice site)	Increased	4R	None	MSTD	Neuronal and glial inclusions	151
E10+12 (C to T)	I10 (5′ splice site)	Increased	4R	None	"FTD Kumamoto"	Neuronal and glial inclusions	163
E10+13 (C to T)	I10 (5′ splice site)	Increased	4R	None	N/A	N/A	164
E10+14 (C to T)	I10 (5′ splice site)	Increased	4R	None	DDPAC	Ballooned neurons with tau staining	145, 164
E10+16 (C to T)	I10 (5′ splice site)	Increased	4R	None	"Australian" pedigree and PSG	Neuronal and glial inclusions	164, 165
E10+33	I10 (5′ splice site)	Increased	4R	ND	N/A	N/A	162

C-term, carboxyterminus; E, exon; I, intron; IR, interrepeat region; N-term, amino-terminus; R, MT-binding repeat.
[a]Hutton M, personal communication.

amount of 4R tau isoforms that are not bound to MTs. This abnormal increase of free tau may result in the formation of insoluble tau aggregates and consequently neurodegeneration.

The second hypothetical pathogenic mechanism to account for brain degeneration in FTDP-17 owing to other tau gene mutations suggests that these mutations directly cause deficits in the abilities of tau to bind to MTs and promote assembly and stability of MTs. This disease mechanism has been linked to several tau gene missense mutations including: G272V, ΔK280, P301L, P301S, V337M G389R, and R406W by *in vitro* studies (111,159,166). On the other hand, the mutations that increase E10 splicing do not have similar effects on the functions of tau (111, 159). Nonetheless, a loss of the binding ability of tau to MTs may produce an increase in the levels of free tau proteins in the neuronal cytoplasm, and this could promote their fibrillogenesis. Mutant tau proteins are also likely to accelerate the accumulation of insoluble tau filaments within neurons. This notion has been supported by several studies of the *in vitro* assembly of tau filaments, which also demonstrated that tau filament formation is enhanced by heparin using recombinant G272, P301L, V337M, and R406W tau mutant proteins compared to wild-type tau protein (172,173). Moreover, mutations in exons other than those in E10 (i.e., V337M and R406W) promote tau aggregation composed of all six isoforms, whereas other E10 mutations (i.e., P301L) increase 4R tau in insoluble FTDP-17 brain fractions (111,145). Although there are preliminary data to account for the differential effects of these mutations, additional studies are needed to fully elucidate how they cause diverse FTDP-17 syndromes.

DEVELOPMENT OF EXPERIMENTAL ANIMAL MODELS OF FILAMENTOUS TAU PATHOLOGY

The discovery of tau gene mutations pathogenic for FTDP-17 indicates that genetic abnormalities directly influence the levels or functions of tau proteins, thereby resulting in the aggregation of insoluble tau and neurodegeneration. However, it is difficult to specify the precise underlying mechanisms whereby these mutations cause distinct biochemical, neuropathologic, and phenotypic abnormalities in FTDP-17 syndromes that vary from patient to patient by analyzing human cases because of the following reasons: (a) limited sample size of kindreds with each mutation; (b) the difficulty of conducting biochemical and pathologic studies in early stages of the disease; and (c) the possibility that several additional but as yet unknown environmental and/or genetic factors might modify the biochemical and clinicopathologic phenotype of FTDP-17. Accordingly, animal models that reproduce tauopathies are required for better understanding of the central roles played by tau abnormalities in neurodegenerative disorders. Such models are also expected to be useful for assessing methods of early diagnosis and the effectiveness of therapeutic agents for the treatment of neurodegenerative tauopathies.

The strategies for making animal models that recapitulate tauopathies are summarized in the following and include:

1. Selection of DNA constructs to be expressed in the CNS of the model, and the use of cDNA or genomic DNA tau constructs is a straightforward strategy to induce accumulations of tau in the CNS of experimental animals. Indeed, tau cDNAs or minigenes have been used to overexpress specific tau isoform(s), and cause an imbalance of the tau isoform profile similar to that seen in human tauopathies. Further, animal models engineered to express human genomic tau DNA using bacterial artificial chromosome (BAC) or a P1-derived artificial chromosome (PAC) containing the entire tau gene may be informative for elucidating the biochemistry (including E10 splicing) and neuropathology (including emergence of tau deposits) in animals with and without a tau gene mutation. Other possible strategies to generate animal models of tauopathies are to express proteins that regulate the phosphorylation of tau proteins, or to express APP, PS-1, and PS-2 in tau transgenic (Tg) animals to investigate the interaction of these molecules with tau to model tauopathies that show coexistence of tau and amyloid pathologies.
2. Overexpression of tau without mutation to assess the effects of excess tau proteins in the cytoplasm of neurons and glia on the formation of tau aggregates. Because animal models expressing a mutant human tau gene may reproduce the biochemical and pathologic abnormalities in FTDP-17, it is necessary to do this by expressing mutations such as ΔK280, P301L, V337M, and R406W, because they impair the ability of tau to bind to MTs and promote assembly and stability of MTs. Further, the generation of tau DNA with mutations that alter the splicing of E10 to produce animal models would be informative using the entire gene or minigene of human tau. However, the phenotypes of these mutant tau animals should be assessed in comparison with animals showing a similar expression level of wild-type human tau.
3. Use of neuron-specific promoters including the Thy-1, 3-hydroxy-3-methylglutaryl coenzyme A reductase (HMG-CoA) and prion protein (PrP) promoters to generate tau pathology in neurons, whereas animals showing glial tau pathology can be developed by using glia-specific promoters including glial fibrillary acid protein (GFAP) promoter for astrocytes and 2′,3′-cyclin-nucleotide phosphodiesterase (CNP) and myelin basic protein (MBP) promoters for oligodendrocytes. Tg animals with genomic DNA are generally driven by endogenous promoters.

The generation of a tau Tg mouse using a cDNA for the longest tau isoform (T40, 4R2N tau) combined with Thy-1 promoter was reported in 1995 (174), followed by a study of tau Tg mice expressing the shortest tau isoform (T44 or fetal tau, 3R0N tau) driven by the HMG-CoA reductase promoter (175). In these studies, somatodendritic overexpression of human tau was observed using anti-phospho-tau antibodies. However, these Tg mice did not show tau aggregates in any of the CNS regions nor other tauopathy-like phenotypic changes, probably owing to the low expression level of the transgene product. Filamentous tau aggregates have been observed in the spinal cord and brainstem of tau Tg mice generated by using a transgene consisting of fetal tau and the PrP promoter (176) (Fig. 94.5). This Tg mouse showed approximately ninefold more tau protein than the wild-type control, and thus the successful development of tau inclusions is presumably owing to the high expression levels of human tau. The tau aggregates in this Tg mouse are spheroidal inclusions in proximal axons, and they showed an increase in number with aging, consistent with an age-dependent increase in the extent of tau phosphorylation and an age-dependent decrease in the solubility of overexpressed human tau. In addition, this tau Tg mouse showed axonal degeneration and reduced axonal transport as well as motor weakness. Hence, this Tg mouse is thought to be a good model for age-related neurodegeneration in tauopathies, and it is useful for studying the time course of CNS degeneration in a human tauopathy. The spheroidal tau inclusions in these tau Tg mice have also been shown to contain neurofilaments (NFs) and tubulin. This colocalization of tau and NFs is found in the inclusions of ALS/PDC spinal cord. Further studies using these tau Tg mice crossed with NF-knockout mice could be informative by determining whether or not NFs promote the formation of tau aggregates, and whether or not tau can form aggregates in the absence of NFs.

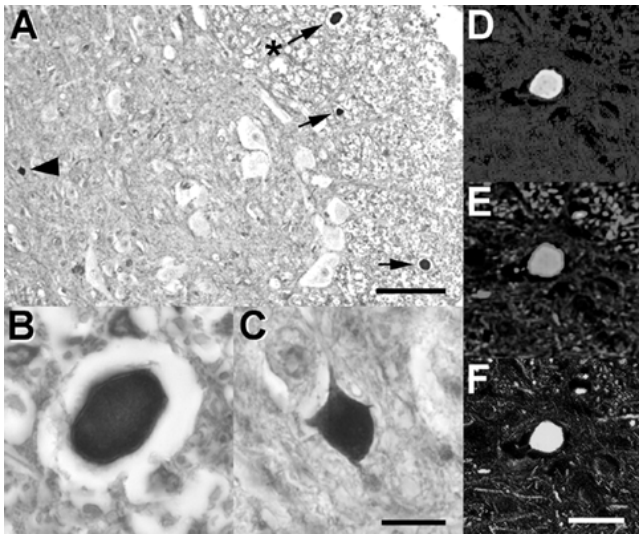

FIGURE 94.5. Spheroidal tau deposits in the spinal cord of tau Tg mice over-expressing the shortest human tau isoform. **A:** Low power field of the spinal cord section of a 6-month-old Tg mouse stained with anti-tau antibody T14. Spheroidal deposits *(arrows)* are observed in axons, and somatodendritic tau stain *(arrowhead)* is found in the neuron. **B:** Higher magnification of the spheroidal tau deposit indicated with asterisk in *(A)*. **C:** Higher magnification of the somatodendritic tau stain shown in *(A)*. **D,E,F:** Triple-labeled indirect immunofluorescence of the spinal cord deposit from a 6-month-old Tg mouse. Blue, anti-tau antibody T14 and AMCA *(D)*; red, anti-low-molecular-mass-neurofilament (NFL) antibody and Text Red *(E)*; and green, anti-high-molecular-mass-neurofilament (NFH) antibody and FITC *(F)*. Note that tau is colocalized with neurofilaments in the spheroid deposits. Scale bar, 50 μm *(A)*; 10 μm *(B,C)*; and 10 μm *(D,E,F)*.

Tau Tg mice with the T40 transgene combined with the Thy-1 promoter have been developed recently (177,178). These mice exhibit spheroidal tau inclusions in axons of the spinal cord and brainstem as well as cerebral cortex, and the colocalization of tau and NFs has also observed in these inclusions. Axonal degeneration and corresponding phenotypic changes were found in these Tg mice, and thus they may be regarded as models of neurodegenerative tauopathies with increased 4R tau. In addition, these 4R tau Tg mice showed somatodendritic tau expression to a greater extent than 3R tau Tg mice. This suggests that the difference in affected brain areas between 4R tau and 3R tau Tg mice as well as the effect of predominant tau isoforms on the distribution of pathology should be analyzed by using tau Tg mice with the same promoter and a similar expression level of human tau.

To date, only a few genomic tau Tg mice using PAC and BAC have been generated, and they have shown a somatodendritic pattern of phosphorylated tau expression (179). Although all of the mentioned tau Tg mice have shown a somatodendritic tau expression that resembles the "pretangles" in AD, none of them have developed NFTs containing a β-pleated sheet structure that can be recognized by thioflavin-S and Congo red. In fact, overexpressed tau in the cytoplasm and processes of neurons is rather diffuse and does not show a filamentous structure by EM (179). One possible method to generate NFTs in tau Tg mice would be to use a mutant tau gene construct to decrease the ability of tau to regulate MTs. Another method would be to follow tau Tg mice showing an age-related increase of tau pathology to vary advanced ages.

One of the major goals in developing animal models is to generate a model for AD, which is the most common neurodegenerative tauopathy. It seems feasible to develop mice with human APP, PS-1, PS-2, and ApoE transgenes to elucidate the mechanism of biochemical and clinicopathologic changes caused by genetic abnormalities in AD. Tg mice overexpressing APP with FAD mutations have shown diffuse and neuritic Aβ plaques in the brain, but they have lacked tau-positive NFTs and neuron loss (180–182). Moreover, Tg mice with a PS-1 transgene linked to FAD

with and without a mutant APP transgene have developed no tau pathology (183). Taking together, these studies suggest that the generation of Aβ plaques in mice is not sufficient to model AD pathology and to elucidate interactions between tau and Aβ pathologies in the pathogenesis of AD. Thus, the generation of double Tg mouse overexpressing tau and mutant APP, and ''humanized'' genomic tau Tg mouse with tau-knockout mice to over-express only the six human tau isoforms may be better strategies to develop Tg mouse models recapitulating AD pathology.

CONCLUSION

Genetic, biochemical, and pathologic analyses have indicated that tau proteins play a central role in the pathogenesis of various neurodegenerative tauopathies, including AD. Transgenic experiments have also shown that overexpression of tau can cause neurodegenerative tauopathies in experimental animals. However, genetic abnormalities that influence tau phosphorylation and/or functions of tau in AD remain unsettled. The mutations on APP, PS-1, and PS-2, polymorphism of ApoE and other yet-to-be-identified genetic susceptibilities as well as environmental factors may promote the dysfunction of tau in AD. Among other tauopathies, genetic abnormalities have been confirmed only in FTDP-17 kindreds. The onset of PSP has been associated with an intronic polymorphism in the tau gene (184), but the major genetic factors that cause tau aggregation and neurodegeneration in many tauopathies are still to be elucidated.

REFERENCES

1. The National Institute on Aging, and Reagan Institute Working Group on Diagnostic Criteria for the Neuropathologic Assessment of Alzheimer's Disease: consensus recommendations for the postmortem diagnosis of Alzheimer's disease (review; 68 refs). *Neurobiol Aging* 1997;18:S1–S2.
2. Goedert M, Trojanowski JQ, Lee VMY. The neurofibrillary pathology of Alzheimer's disease. In: Prusiner SB, Rosenberg RN, Di Mauro S, et al, eds. *The molecular and genetic basis of neurological diseases,* second ed. Boston: Butterworth Heineman, 1997:613–627.
3. St. George-Hyslop P, Tanzi RE, Polinsky RJ, et al. The genetic defect causing familial Alzheimer's disease maps on chromosome 21. *Science* 1987;235:885–890.
4. St. George-Hyslop P, Haines J, Rogaev E, et al. Genetic evidence for a novel familial Alzheimer's disease locus on chromosome 14. *Nat Genet* 1992;2:330–334.
5. Levy-Lahad E, Wijsman EM, Nemens E, et al. A familial Alzheimer's disease locus on chromosome 1. *Science* 1995;269: 970–973.
6. Levy-Lahad E, Wasco W, Poorkaj P, et al. Candidate gene for the chromosome 1 familial Alzheimer's disease locus. *Science* 1995:269:973–977.
7. Sherrington R, Rogaev EI, Liang Y, et al. Cloning of a gene bearing missense mutations in early-onset familial Alzheimer's disease. *Nature* 1995;375:754–760.
8. Strittmatter WJ, Saunders AM, Schmechel D, et al. Apolipoprotein E: high avidity binding to beta-amyloid and increased freqency of type 4 allele in late-onset familial Alzheimer's disease. *Proc Natl Acad Sci USA* 1993;92:4725–4727.
9. Saunders AM, Strittmatter, WJ, Schmechel D, et al. Association of apolipoprotein E allele epsilon 4 with late-onset familial and sporadic Alzheimer's disease. *Neurology* 1993;43:1467–1472.
10. McKee AC, Kosik KS, Kowall NW. Neuritic pathology and dementia in Alzheimer's disease. *Ann Neurol* 1991;30:156–165.
11. Arriagada PV, Growdon JH, Hedley-Whyte ET, et al. Neurofibrillary tangles but not senile plaques parallel duration and severity of Alzheimer's disease. *Neurology* 1992;42:631–639.
12. Dickson DW, Crystal HA, Mattiace LA, et al. Identification of normal and pathologic aging in prospectively studied nondemented elderly humans. *Neurobiol Aging* 1992;13:179-189.
13. Neve RL, Robakis NK. Alzheimer's disease: a re-examination of the amyloid hypothesis. *Trends Neurosci* 1998;21:15–19.
14. Bancher C, Jellinger KA. Neurofibrillary tangle predominant form of senile dementia of Alzheimer type: a rare subtype in very old subjects. *Acta Neuropathol (Berl)* 1994;88:565–570.
15. Braak H, Braak E. Neuropathologic stageing of Alzheimer-related changes. *Acta Neuropathol (Berl)* 1991;82:239–259.
16. Giaccone G, Tagliavini F, Linoli G, et al. Down patients: extracellular preamyloid deposits precede neuritic degeneration and senile plaques. *Neurosci Lett* 1989;97:232–238.
17. Flament S, Delacourte A, Mann DM. Phosphorylation of tau proteins: a major event during the process of neurofibrillary degeneration. A comparative study between Alzheimer's disease and Down's syndrome. *Brain Res* 1990;516:15–19.
18. Roberts GW, Allsop D, Bruton C. The occult aftermath of boxing. *J Neurol Neurosurg Psychiatry* 1990;53:373–378.
19. Mendell JR, Sahenk Z, Gales T, et al. Amyloid filaments in inclusion body myositis: novel findings provide insight into nature of filaments. *Arch Neurol* 1991;48:1229–1234.
20. Askanas V, Engel WK, Alvarez RB. Light and electron microscopic localization of beta-amyloid protein in muscle biopsies of patients with inclusion-body myositis. *Am J Pathol* 1992; 141:31–36.
21. Askanas V, Engel WK, Bilak M, et al. Twisted tubulofilaments of inclusion body myositis muscle resemble paired helical filaments of Alzheimer brain and contain hyperphosphorylated tau. *Am J Pathol* 1994;144:177–187.
22. Ghetti B, Tagliavini F, Masters CL, et al. Gerstmann-Straussler-Scheinkerdisease: II. Neurofibrillary tangles and plaques with PrP-amyloid coexist in an affected family. *Neurology* 1989;39: 1453–1461.
23. Tagliavini F, Giaccone G, Prelli F, et al. Aa68 is a component of paired helical filaments of Gerstmann-Straussler-Sheinker disease, Indiana kindred. *Brain Res* 1993;616:325–329.
24. Hsiao K, Dlouhy SR, Farlow MR, et al. Mutant prion proteins in Gerstmann-Straussler-Scheinker disease with neurofibrillary tangles. *Nat Genet* 1992;1:68–71.
25. Ghetti B, Piccardo P, Spillantini MG, et al. Vascular variant of prion protein cerebral amyloidosis with tau-positive neurofibrillary tangles: the phenotype of the stop codon 145 mutation in PRNP. *Proc Natl Acad Sci USA* 1996;93:744–748.
26. Hirano A, Malamud N, Kurland LT. Parkinsonism dementia complex in endemic disease on the island of Guam—pathologic features. *Brain* 1961;84:662.
27. Hof PR, Nimchinsky EA, Buée-Scherrer V, et al. Amyotrophic lateral sclerosis/parkinsonism-dementia complex of Guam:

quantitative neuropathology, immunohistochemical analysis of neuronal vulnerability, and comparison with related neurodegenerative disorders. *Acta Neuropathol (Berl)* 1994;88:397–404.
28. Umahara T, Hirano A, Kato S, et al. Demonstration of neurofibrillary tangles and neuropil thread-like structures in spinal cord white matter in parkinsonism-dementia complex on Guam and in Guamanian amyotrophic lateral sclerosis. *Acta Neuropatholo (Berl)* 1994;88:180–184.
29. Buée-Scherrer V, Buee L, Hof PR, et al. Neurofibrillary degeneration in amyotrophic lateral sclerosis/parkinsonism-dementia complex of Guam: immunochemical characterization of tau proteins. *Am J Pathol* 1995;146:924–932.
30. Braak H, Braak E. Argyrophilic grains: characteristic pathology of cerebral cortex in cases of adult onset dementia without Alzheimer changes. *Neurosci Lett* 1987;76:124–127.
31. Itagaki S, McGeer PL, Akiyama H, et al. A case of adult-onset dementia with argyrophilic grains. *Ann Neurol* 1989;26:685–689.
32. Perry G, Stwart D, Friedman R, et al. Filaments of Pick's bodies contain altered cytoskeletal elements. *Am J Pathol* 1987;127:559–568.
33. Murayama S, Mori H, Ihara Y, et al. Immunocytochemical and ultrastructural studies of Pick disease. *Ann Neurol* 1990;27:394–405.
34. Lieberman AP, Trojanowski JQ, Lee VMY, et al. Cognitive, neuroimaging, and pathologic studies in a patient with Pick disease. *Ann Neurol* 1998;43:259–265.
35. Paulus W, Selim M. Corticonigral degeneration with neuronal achromasia and basal neurofibrillary tangles. *Acta Neuropathol (Berl)* 1990;81:89–94.
36. Ksiezak-Reding H, Morgan K, Mattiace LA, et al. Ultrastructure and biochemical composition of paired helical filaments in corticobasal degeneration. *Am J Pathol* 1994;145:1496–1508.
37. Mori H, Nishimura M, Namba Y, et al. Corticobasal degeneration: a disease with widespread appearance of abnormal tau and neurofibrillary tangles, and its relation to progressive supranuclear palsy. *Acta Neuropathol (Berl)* 1994;88:113–121.
38. Wakabayashi K, Oyanagi K, Makifuchi T, et al. Corticobasal degeneration: etiopathologic significance of the cytoskeletal alterations. *Acta Neuropathol (Berl)* 1994;87:545–553.
39. Bancher C, Lassmann H, Budka H, et al. Neurofibrillary tangles in Alzheimer's disease and progressive supranuclear palsy: antigenic similarities and differences. Microtubule-associated protein tau antigenicity is prominent in all types of tangles. *Acta Neuropathol (Berl)* 1987;74:39–46.
40. Flament S, Delacourte A, Verny M, et al. Abnormal tau proteins in progressive supranuclear palsy: similarities and differences with the neurofibrillary degeneration of the Alzheimer type. *Acta Neuropathol (Berl)* 1991;81:591–596.
41. Schmidt ML, Huang R, Martin JA, et al. Neurofibrillary tangles in progressive supranuclear palsy contain the same tau epitopes identified in Alzheimer's disease PHF-tau. *J Neuropathol Exp Neurol* 1996;55:534–539.
42. Papp MI, Kahn JE, Lantos PL. Glial cytoplasmic inclusions in the CNS of patients with multiple system atrophy (striatonigral degeneration, olivopontocerebellar atrophy and Shy-Drager syndrome). *J Neurol Sci* 1989;94:79–100.
43. Auer IA, Schmidt ML, Lee VMY, et al. Paired helical filament tau (PHFtau) in Niemann-Pick type C disease is similar to PHFtau in Alzheimer's disease. *Acta Neuropathol (Berl)* 1995;90:547–551.
44. Love S, Bridges LR, Case CP. Neurofibrillary tangles in Niemann-Pick disease type C. *Brain* 1995;188:119–129.
45. Suzuki K, Parker CC, Pentchev PG, et al. Neurofibrillary tangles in Niemann-Pick disease type C. *Acta Neuropathol (Berl)* 1995;89:227–238.
46. Kosaka K. Diffuse neurofibrillary tangles with calcification: a new presenile dementia. *J Neurol Neurosurg Psychiatry* 1994;57:594–596.
47. Eidelberg D, Sotrel A, Joachim C, et al. Adult onset Hallervorden-Spatz disease with neurofibrillary pathology: a discrete clinico-pathologic entity. *Brain* 1987;110:993–1013.
48. McQuaid S, Allen IV, McMahon J, et al. Association of measles virus with neurofibrillary tangles in subacute sclerosing panencephalitis: a combined in situ hybridization and immunocytochemical investigation. *Neuropathol Appl Neurobiol* 1994;20:103–110.
49. Wilhelmsen KC, Lynch T, Pavlou E, et al. Localization of disinhibition-dementia-parkinsonism-amyotrophy complex to 17q21-22. *Am J Hum Gen* 1994;55:1159–1165.
50. Foster NL, Wilhelmsen K, Sima AA, et al. Frontotemporal dementia and parkinsonism linked to chromosome 17: a consensus conference. Conference participants. *Ann Neurol* 1997;41:706–715.
51. Papp MI, Lantos PL. Accumulation of tubular structures in oligodendroglial and neuronal cells as the basic alteration in multiple system atrophy. *J Neurol Sci* 1992;107:172–182.
52. Nishimura M, Namba Y, Ikeda K, et al. Glial fibrillary tangles with straight tubules in the brains of patients with progressive supranuclear palsy. *Neurosci Lett* 1992;143:35–38.
53. Iwatsubo T, Hasegawa M, Ihara Y. Neuronal and glial tau-positive inclusions in diverse neurologic diseases share common phosphorylation characteristics. *Acta Neuropathol* 1994;88:129–136.
54. Yamaoka LH, Welsh-Bohmer KA, Hulette CM, et al. Linkage of frontotemporal dementia to chromosome 17: clinical and neuropathologic characterization of phenotype. *Am J Hum Gen* 1996;59:1306–1312.
55. Wijker M, Wszolek ZK, Wolters EC, et al. Localization of the gene for rapidly progressive autosomal dominant parkinsonism and dementia with pollido-ponto-nigral degeneration to chromosome 17q21. *Hum Mol Genet* 1996;5:151–154.
56. Barker M, Kwok JB, Kucera S, et al. Localization of frontotemporal dementia with parkinsonism in an Australian kindred to chromosome 17q21-22. *Ann Neurol* 1997;42:794–798.
57. Froelich S, Basun H, Forsell C, et al. Mapping of a disease locus for familial rapidly progressive frontotemporal dementia to chromosome 17q12-21. *Am J Med Genet* 1997;74:380–385.
58. Murrell JR, Koller D, Foroud T, et al. Familial multiple-system tauopathy with presenile dementia is localized to chromosome 17. *Am J Hum Gen* 1997;61:1131–1138.
59. Wilhelmsen KC. Disinhibition-dementia-parkinsonism-amyotrophy complex (DDPAC) is a non-Alzheimer's frontotemporal dementia. *J Neural Transm Suppl* 1997;49:269–275.
60. Heutink P, Stevens M, Rizzu P, et al. Hereditary frontotemporal dementia is linked to chromosome 17q21-q22: a genetic and clinicopathologic study of three Dutch families. *Ann Neurol* 1997;41:150–159.
61. Spillantini MG, Bird TD, Ghetti B. Frontotemporal dementia and parkinsonism linked to chromosome 17: a new group of tauopathies. *Brain Pathol* 1998;8:387–402.
62. Feany MB, Dickson DW. Neurodegenerative disorders with extensive tau pathology: a comparative study and review. *Ann Neurol* 1996;40:139–148.
63. Chin SS-M, Goldman JE. Glial inclusions in CNS degenerative diseases. *J Neuropathol Exp Neurol* 1996;55:499–508.
64. Spillantini MG, Goedert M, Crowther RA, et al. Familial multiple system tauopathy with presenile dementia: a disease with

abundant neuronal and glial tau filaments. *Proc Natl Acad Sci USA* 1997;94:4113–4118.
65. Fukumoto H, Asami-Okada A, Suzuki N, et al. Association of A beta 40-positive senile plaques with microglial cells in the brains of patients with Alzheimer's disease and in non-demented aged individuals. *Neurodegeneration* 1996;5:13–17.
66. Fukumoto H, Asami-Okada A, Suzuki N, et al. Amyloid beta protein deposition in normal aging has the same characteristics as that in Alzheimer's disease: predominance of A beta 42(43) and association of A beta 40 with cored plaques. *Am J Pathol* 1996;148:259–265.
67. Wisniewski K, Jervis GA, Moretz RC, Wisniewski HM. Alzheimer neurofibrillary tangles in diseases other than senile and presenile dementia. *Ann Neurol* 1979;5:288–294.
68. Braak H, Braak E. Frequency of stages of Alzheimer-related lesions in different age categories. *Neurobiol Aging* 1997;18: 351–357.
69. Kidd M. Paired helical filaments in electron microscopy of Alzheimer's disease. *Nature* 1963;197:192–194.
70. Goedert M, Spillantini MG, Cairns NJ, et al. Tau proteins of Alzheimer paired helical filaments: abnormal phosphorylation of all six brain isoforms. *Neuron* 1992;8:159–168.
71. Crowther RA, Wischik CM. Image reconstruction of the Alzheimer paired helical filament. *EMBO J* 1985;4:3661–3665.
72. Spillantini MG, Crowther RA, Goedert M. Comparison of the neurofibrillary pathology in Alzheimer's disease and familial presenile dementia with tangles. *Acta Neuropathol* 1996;92:42–48.
73. Tagliavini F, Giaccone G, Prelli F, et al. A68 is a component of paired helical filaments of Gerstmann-Straussler-Scheinker disease, Indiana kindred. *Brain Res* 1993;616:325–328.
74. Probst A, Tolnay M, Langui D, et al. Pick disease: hyperphosphorylated tau protein segregates to the somatoaxonal compartment. *Acta Neuropathol* 1996;92:588–596.
75. Spillantini MG, Crowther RA, Kamphorst W et al. Tau pathology in two Dutch families with mutations in the microtubule-binding region of tau. *Am J Pathol* 1998;153:1359–1363.
76. Ksiezak-Reding H, Morgan K, Mattiace LA, et al. Ultrastructure and biochemical composition of paired helical filaments in corticobasal degeneration. *Am J Pathol* 1994;145:1496–1508.
77. Goedert M, Wischik CM, Crowther RA, et al. Cloning and sequencing of the cDNA encoding a core protein of the paired helical filament of Alzheimer disease: identification as the microtubule-associated protein tau. *Proc Natl Acad Sci USA* 1988;85: 4051–4055.
78. Kondo J, Honda T, Mori H, et al. The carboxyl third of tau is tightly bound to paired helical filaments. *Neuron* 1988;1: 827–834.
79. Wischik CM, Novak M, Thogersen HC, et al. Isolation of a gragment of tau derived from the core of the paired helical filament of Alzheimer disease. *Proc Natl Acad Sci USA* 1988; 85:4506–4510.
80. Kosik KS, Orecchio LD, Binder L, et al. Epitopes that span the tau molecule are shared with paired helical filaments. *Neuron* 1988;1:817–825.
81. Lee VMY, Balin BJ, Otvos LJ, et al. A68: a major subunit of paired helical filaments and derivatized forms of normal tau. *Science* 1991;251:675–678.
82. Crowther RA. Straight and paired helical filaments in Alzheimer disease have a common structural unit. *Proc Natl Acad Sci USA* 1991;88:2288–2292.
83. Binder LI, Frankfurter A, Rebhun LI. The distribution of tau in the mammalian central nervous system. *J Cell Biol* 1985;101: 1371–1378.
84. Couchie D, Mavilia C, Georgieff IS, et al. Primary structure of high molecular weight tau present in the peripheral nervous system. *Proc Natl Acad Sci USA* 1992;89:4378–4381.
85. Bernhardt R, Matus A. Light and electron microscopic studies of the distribution of microtubule-associated protein 2 in rat brain: a difference between dendritic and axonal cytoskeletons. *J Comp Neurol* 1984;226:203–221.
86. DeCamilli P, Miller PE, Navone F, et al. Distribution of microtubule-associated protein 2 in the nervous system of the rat studied by immunofluorescence. *Neuroscience* 1984;11: 817–846.
87. Burton PR, Paige JL. Polarity of axoplasmic microtubules in the olfactory nerve of the frog. *Proc Natl Acad Sci USA* 1981; 78:3269–3273.
88. Heidemann SR, Landers JM, Hamborg MA. Polarity orientation of axonal microtubules. *J Cell Biol* 1981;91:661–665.
89. Baas PW, Deitch JS, Black MM, et al. Polarity orientation of microtubules in hippocampal neurons: uniformity in the axon and nonuniformity in the dendrite. *Proc Natl Acad Sci USA* 1988;85:8335–8339.
90. Nadelhaft I. Microtubule densities and total numbers in selected axons of the crayfish abdominal nerve cord. *J Neurocytol* 1974; 3:73–86.
91. Chen J, Kanai Y, Cowan NJ, et al. Projection domains of MAP2 and tau determine spacings between microtubules in dendrites and axons. *Nature* 1992;360:674–677.
92. LoPresti P, Szuchet S, Papasozomenos SC, et al. Functional implications for the microtubule-associated protein tau: localization in oligodendrocytes. *Proc Natl Acad Sci USA* 1995;92: 10369–10373.
93. Shin RW, Iwaki T, Kitamoto T, et al. Hydrated autoclave pretreatment enhances tau immunoreactivity in formalin-fixed normal and Alzheimer's disease brain tissues. *Lab Invest* 1991;64: 693–702.
94. Drubin DG, Feinstein SC, Shooter EM, et al. Nerve growth factor-induced neurite outgrowth in PC12 cells involves the coordinate induction of microtubule assembly and assembly-promoting factors. *J Cell Biol* 1985;101:1799–1807.
95. Drubin D, Kobayashi S, Kellogg D, et al. Regulation of microtubule protein levels during cellular morphogenesis in nerve growth factor-treated PC12 cells. *J Cell Biol* 1988;106: 1583–1591.
96. Ferreira A, Busciglio J, Caceres A. Microtubule formation and neurite growth in cerebellar macroneurons which develop *in vitro*: evidence for the involvement of the microtubule-associated proteins, MAP-1a, HMW-MAP2 and Tau. *Brain Res Dev Brain Res* 1989;49:215–228.
97. Weingarten MD, Lockwood AH, Hwo SY, et al. A protein factor essential for microtubule assembly. *Proc Natl Acad Sci USA* 1975;72:1858–1862.
98. Drechsel DN, Hyman AA, Cobb MH, et al. Modulation of the dynamic instability of tubulin assembly by the microtubule-associated protein tau. *Mol Biol Cell* 1992;3:1141–1154.
99. Cáceres A, Kosik KS. Inhibition of neurite polarity by tau antisense oligonucleotides in primary cerebellar neurons. *Nature* 1990;343:461–463.
100. Cáceres A, Potrebic S, Kosik KS. The effect of tau antisence oligonucleotides on neurite formation of cultured cerebellar macroneurons. *J Neurosci* 1991;11:1515–1523.
101. Harada A, Oguchi K, Okabe S, et al. Altered microtubule organization in small-calibre axons of mice lacking tau protein. *Nature* 1994;369:488–491.
102. Ikegami S, Harada A, Hirokawa N. Muscle weakness, hyperactivity, and impairment in fear conditioning in tau-deficient mice. *Neurosci Lett* 2000;279:129–132.
103. Goedert M, Spillantini MG, Jakes R, et al. Multiple isoforms of human microtubule-associated protein tau: sequences and

localization in neurofibrillary tangles of Alzheimer's disease. *Neuron* 1989;3:519–526.
104. Goedert M, Spillantini MG, Potier MC, et al. Cloning and sequencing of the cDNA encoding an isoform of microtubule-associated protein tau containing four tandem repeats: differential expression of tau protein mRNAs in human brain. *EMBO J* 1989;8:393–399.
105. Andreadis A, Brown WM, Kosik KS. Structure and novel exons of the human tau gene. *Biochemistry* 1992;31:10626–10633.
106. Goedert M, Jakes R. Expression of separate isoforms of human tau protein: correlation with the tau pattern in brain and effects on tubulin polymerization. *EMBO J* 1990;9:4225–4230.
107. Butner KA, Kirschner MW. Tau protein binds to microtubules through a flexible array of distributed weak sites. *J Cell Biol* 1991;115:717–730.
108. Goode BL, Feinstein SC. Identification of a novel microtubule binding and assembly domain in the developmentally regulated inter-repeat region of tau. *J Cell Biol* 1994;124:769–782.
109. Goode BL, Denis PE, Panda D, et al. Functional interactions between the proline-rich and repeat regions of tau enhance microtubule binding and assembly. *Mol Biol Cell* 1997;8:353–365.
110. Goedert M, Spillantini MG, Crowther RA. Cloning of a big tau microtubule-associated protein characteristic of the peripheral nervous system. *Proc Natl Acad Sci USA* 1992;89:1983–1987.
111. Hong M, Zhukareva V, Vogelsberg-Ragaglia V, et al. Mutation-specific functional impairments in distinct tau isoforms of hereditary FTDP-17. *Science* 1998;282:1914–1917.
112. Götz J, Probst A, Spillantini MG, et al. Somatodendritic localization and hyperphosphorylation of tau protein in transgenic mice expressing the longest human brain tau isoform. *EMBO J* 1995;14:1304–1313.
113. Hasegawa M, Morishima-Kawashima M, Takio K, et al. Protein sequence and mass spectrometric analyses of tau in the Alzheimer's disease brain. *J Biol Chem* 1992;267:17047–17054.
114. Morishima-Kawashima M, Hasegawa M, Takio K, et al. Proline-directed and non-proline-directed phosphorylation of PHF-tau. *J Biol Chem* 1995;270:823–829.
115. Hagestedt T, Lichtenberg B, Wille H, et al. Tau protein becomes long and stiff upon phosphorylation: correlation between paracrystalline structure and degree of phosphorylation. *J Cell Biol* 1989;109:1643–1651.
116. Biernat J, Gustke N, Drewes G, et al. Phosphorylation of Ser262 strongly reduces binding of tau to microtubules: distinction between PHF-like immunoreactivity and microtubule binding. *Neuron* 1993;11:153–163.
117. Bramblett GT, Goedert M, Jakes R, et al. Abnormal tau phosphorylation at Ser396 in Alzheimer's disease recapitulates development and contributes to reduced microtubule binding. *Neuron* 1993;10:1089–1099.
118. Yoshida H, Ihara Y. Tau in paired helical filaments is functionally distinct from fetal tau: assembly incompetence of paired helical filament-tau. *J Neurochem* 1993;61:1183–1186.
119. Biernat J, Gustke N, Drewes G, et al. Phosphorylation of Ser262 strongly reduces binding of tau to microtubules: distinction between PHF-like immunoreactivity and microtubule binding. *Neuron* 1993;11:153–163.
120. Lindwall G, Cole RD. Phosphorylation affects the ability of tau protein to promote microtubule assembly. *J Biol Chem* 1984;259:5301–5305.
121. Drechsel DN, Hyman AA, Cobb MH, et al. Modulation of the dynamic instability of tubulin assembly by the microtubule associated protein tau. *Mol Biol Cell* 1992;3:1141–1154.
122. Trinczek B, Biernat J, Baumann K, et al. Domains of tau protein, differential phosphorylation, and dynamic instability of microtubules. *Mol Biol Cell* 1995;6:1887–1902.
123. Drewes G, Lichtenberg-Kraag B, Doring F, et al. Mitogen activated protein (MAP) kinase transforms tau protein into an Alzheimer-like state. *EMBO J* 1992;11:2131–2138.
124. Drewes G, Mandelkow EM, Baumann K, et al. Dephosphorylation of tau protein and Alzheimer paired helical filaments by calcineurin and phosphatase-2A. *FEBS Lett* 1993;336:425–432.
125. Seubert P, Mawal-Dewan M, Barbour R, et al. Detection of phosphorylated Ser262 in fetal tau, adult tau, and paired helical filament tau. *J Biol Chem* 1995;270:18917–18922.
126. Goedert M, Jakes R, Crowther RA, et al. The abnormal phosphrylation of tau protein at Ser-202 in Alzheimer disease recapitulates phosphorylation during development. *Proc Natl Acad Sci USA* 1993;90:5066–5070.
127. Garver TD, Harris KA, Lehman RA, et al. Tau phosphorylation in human, primate, and rat brain: evidence that a pool of tau is highly phosphorylated in vivo and is rapidly dephosphorylated in vitro. *J Neurochem* 1994;63:2279–2287.
128. Matsuo ES, Shin RW, Billingsley ML, et al. Biopsy-derived adult human brain tau is phosphorylated at many of the same sites as Alzheimer's disease paired helical filament tau. *Neuron* 1994;13:989–1002.
129. Hoffmann R, Lee VMY, Leight S, et al. Unique Alzheimer's disease paired helical filament specific epitopes involve double phosphorylation at specific sites. *Biochemistry* 1997;36:8114–8124.
130. Zheng-Fischhofer Q, Biernat J, Mandelkow EM, et al. Sequential phosphorylation of tau by glycogen synthase kinase-3beta and protein kinase A at Thr212 and Ser214 generates the Alzheimer-specific epitope of antibody AT100 and requires a paired-helical filament-like conformation. *Eur J Biochem* 1998;252:542–552.
131. Ishiguro K, Takamatsu M, Tomizawa K, et al. Tau protein kinase I converts normal tau protein into A68-like component of paired helical filaments. *J Biol Chem* 1992;267:10897–10901.
132. Hosoi T, Uchiyama M, Okamura E, et al. Evidence for cdk5 as a major activity phosphorylating tau protein in porcine brain extract. *J Biochem* 1995;117:741–749.
133. Hong M, Lee VMY. Insulin and insulin-like growth factor-1 regulate tau phosphorylation in cultured human neurons. *J Biol Chem* 1997;272:19547–19553.
134. Woodgett JR. Molecular cloning and expression of glycogen synthase kinase-3/factor A. *EMBO J* 1990;9:2431–2438.
135. Tsai LH, Delalle I, Caviness VS Jr, et al. p35 is a neural-specific regulatory subunit of cyclin-dependent kinase 5. *Nature* 1994;371:419–423.
136. Lew J, Huang QQ, Qi Z, et al. A brain-specific activator of cyclin-dependent kinase 5. *Nature* 1994;371:423–426.
137. Patrick GN, Zukerberg L, Nikolic M, et al. Conversion of p35 to p25 deregulates Cdk5 activity and promotes neurodegeneration. *Nature* 1999;402:615–622.
138. Merrick SE, Demoise DC, Lee VMY. Site-specific dephosphorylation of tau protein at Ser202/Thr205 in response to microtubule depolymerization in cultured human neurons involves protein phosphatase 2A. *J Biol Chem* 1996;271:5589–5594.
139. Harris KA, Oyler GA, Doolittle GM, et al. Okadaic acid induces hyperphosphorylated forms of tau protein in human brain slices. *Ann Neurol* 1993;33:77–87.
140. Sontag E, Nunbhakdi-Craig V, Bloom GS, et al. A novel pool of protein phophatase 2A is associated with microtubules and is regulated during the cell cycle. *J Cell Biol* 1995;128:1131–1144.
140a. Vogelsberg-Ragaglia V, Schuck T, Trojanowski JQ, et al. PP2A mRNA expression is quantitatively decreased in Alzheimer's disease hippocampus. *Exp Neurol* 2001;168:402–412.

141. Buee SV, Hof PR, Buee L, et al. Hyperphosphorylated tau proteins differentiate corticobasal degeneration and Pick disease. *Acta Neuropathol (Berl)* 1996;91:351–359.
142. Sergeant N, David JP, Lefranc D, et al. Different distribution of phosphorylated tau protein isoforms in Alzheimer's and Pick diseases. *FEBS Letters.* 1997;412:578–582.
143. Delacourte A, Sergeant N, Wattez A, et al. Vulnerable neuronal subsets in Alzheimer's and Pick disease are distinguished by their tau isoform distribution and phosphorylation. *Ann Neurol* 1998;43:193–204.
144. Reed LA, Grabowski TJ, Schmidt ML, et al. Autosomal dominant dementia with widespread neurofibrillary tangles. *Ann Neurol* 1997;42:564–572.
145. Clark LN, Poorkaj P, Wszolek ZK, et al. Pathogenic implications of mutations in the tau gene in pallido-ponto-nigral degeneration and related chromosome 17-linked neurodegenerative disorders. *Proc Natl Acad Sci USA* 1998;95:13103–13107.
146. Bird TD, Wijsman EM, Nochlin D, et al. Chromosome 17 and hereditary dementia: linkage studies in three non-Alzheimer families and kindreds with late-onset FAD. *Neurology* 1997;48: 949–954.
147. Wszolek ZK, Pfeiffer RF, Bhatt MH, et al. Rapidly progressive autosomal dominant parkinsonism and dementia with pallido-ponto-nigral degeneration. *Ann Neurol* 1992;32:312–320.
148. Lynch T, Sano M, Marder KS, et al. Clinical characteristics of a family with chromosome 17-linked disinhibition-dementia-parkinsonism-amyotrophy complex. *Neurology* 1994;44: 1878–1884.
149. Spillantini MG, Bird TD, Ghetti B. Frontotemporal dementia and parkinsonism linked to chromosome 17: a new group of tauopathies. *Brain Pathol* 1998;8:387–402.
150. Reed LA, Schmidt ML, Wszolek ZK, et al. The neuropathology of a chromosome 17-linked autosomal dominant parkinsonism and dementia ("pallido-ponto-nigral degeneration"). *J Neuropathol Exp Neurol* 1998;57:588–610.
151. Spillantini MG, Murrell JR, Goedert M, et al. Mutation in the tau gene in familial multiple system tauopathy with presenile dementia. *Proc Natl Acad Sci USA* 1998;95:7737–7741.
152. Murrell JR, Koller D, Foroud T, et al. Familial multiple-system tauopathy with presenile dementia is localized to chromosome 17. *Am J Hum Gen* 1997;61:1131–1138.
153. Lendon CL, Lynch T, Norton J, et al. Hereditary dysphasic disinhibition dementia: a frontotemporal dementia linked to 17q21-22. *Neurology* 1998;50:1546–1555.
154. Hutton M, Lendon CL, Rizzu P, et al. Association of missense and 5′-splice-site mutations in tau with the inherited dementia FTDP-17. *Nature* 1998;393:702–705.
155. Poorkaj P, Bird TD, Wijsman E, et al. Tau is a candidate gene for chromosome 17 frontotemporal dementia. *Ann Neurol* 1998;43:815–825.
156. Bugiani O, Murrell JR, Giaccone G, et al. Frontotemporal dementia and corticobasal degeneration in a family with a P301S mutation in tau. *J Neuropathol Exp Neurol* 1999;58:667–677.
157. Sperfeld AD, Collatz MB, Baier H, et al. FTDP-17: an early-onset phenotype with parkinsonism and epileptic seizures caused by a novel mutation. *Ann Neurol* 1999;46:708–715.
158. Iijima M, Tabira T, Poorkaj P, et al. A distinct familial presenile dementia with a novel missense mutation in the tau gene. *Neuroreport* 1999;10:497–501.
159. D'Souza I, Poorkaj P, Hong M, et al. Missense and silent mutations in tau cause FTDP-17 by altering alternative splicing. *Proc Natl Acad Sci USA* 1999;96:55598—55603.
160. Murrell JR, Spillantini MG, Zolo P, et al. Tau gene mutation G389R causes a tauopathy with abundant pick body-like inclusions and axonal deposits. *J Neuropathol Exp Neurol* 1999;58: 1207–1226.
161. Stanford PM, Halliday GM, Brooks WS, et al. Progressive supranuclear palsy pathology caused by a novel silent mutation in exon 10 of the tau gene: expansion of the disease phenotype caused by tau gene mutations. *Brain* 2000;123:880–893.
162. Rizzu P, Van Swieten JC, Joosse M, et al. High prevalence of mutations in the microtubule-associated protein tau in a population study of frontotemporal dementia in the Netherlands. *Am J Hum Gen* 1999;64:414–421.
163. Yasuda M, Takamatsu J, D'Souza I, et al. A novel mutation at position +12 in the intron following exon 10 of the tau gene in familial frontotemporal dementia (FTD-Kumamoto). *Ann Neurol* 2000;47:422–429.
164. Morris HR, Perez-Tur J, Janssen JC, et al. Mutation in the tau exon 10 splice site region in familial frontotemporal dementia. *Ann Neurol* 1999;45:270–271.
165. Goedert M, Spillantini MG, Crowther RA, et al. Tau gene mutation in familial progressive subcortical gliosis. *Nat Med* 1999;5:454–457.
166. Hasegawa M, Smith MJ, Goedert M. Tau proteins with FTDP-17 mutations have a reduced ability to promote microtubule assembly. *FEBS Lett* 1998;437:207–210.
167. Senapathy P, Shapiro MB, Harris NL. Splice junctions, branch point sites, and exons: sequence statistics, identification, and applications to genome project. *Meth Enzynmol* 1990;183: 252–278.
168. Xu R, Teng J, Cooper TA. The cardiac troponin T alternative exon contains a novel purine-rich positive splicing element. *Mol Cell Biol* 1993;13:3660–3674.
169. Watakabe A, Tanaka K, Shimura Y. The role of exon sequences in splice site selection. *Genes Dev* 1993;7:407–418.
170. Laviqueur A, La BH, Komblihtt AR, et al. A splicing enhancer in the human fibronectin alternate ED1 exon interacts with SR proteins and stimulates U2 snRNP binding. *Gene Dev* 1993;7: 2405–2417.
171. Cooper TA, Mattox W. The regulation of splice-site selection, and its role in human disease. *Am J Hum Gen* 1997;61: 259–266.
172. Arrasate M, Perez M, Armas-Portela R, et al. Polymerization of tau peptides into fibrillar structures. The effect of FTDP-17 mutations. *FEBS Lett* 1999;446:199–202.
173. Nacharaju P, Lewis J, Easson C, et al. Accelerated filament formation from tau protein with specific FTDP-17 missense mutations *FEBS Lett* 1999;447:195–199.
174. Götz J, Probst A, Spillantini MG, et al. Somatodendritic localization and hyperphosphorylation of tau protein in transgenic mice expressing the longest human brain tau isoform. *EMBO J* 1995;14:1304–1313.
175. Brion JP, Tremp G, Octave JN. Transgenic expression of the shortest human tau affects its compartmentalization and its phosphorylation as in the pretangle stage of Alzheimer's disease. *Am J Pathol* 1999;154:255–270.
176. Ishihara T, Hong M, Zhang B, et al. Age-dependent emergence and progression of a tauopathy in transgenic mice overexpressing the shortest human tau isoform. *Neuron* 1999;24:751–762.
177. Spittaels K, Van den HC, Van Dorpe J, et al. Prominent axonopathy in the brain and spinal cord of transgenic mice overexpressing four-repeat human tau protein. *Am J Pathol* 1999;155: 2153–21659.
178. Probst A, Götz J, Wiederhold KH, et al. Axonopathy and amyotrophy in mice transgenic for human four-repeat tau protein. *Acta Neuropathol (Berl)* 2000;99:469–481.
179. Duff K, Knight H, Refolo LM, et al. Characterization of pathology in transgenic mice over-expressing human genomic and cDNA tau transgenes. *Neurobiol Dis* 2000;7:87–98.

180. Games D, Adams D, Alessandrini R, et al. Alzheimer-type neuropathology in transgenic mice overexpressing V717F beta-amyloid precursor protein. *Nature* 1995;373:523–527.
181. Hsiao K, Chapman P, Nilsen S, et al. Correlative memory deficits, Abeta elevation, and amyloid plaques in transgenic mice. *Science* 1996;274:99–102.
182. Irizarry MC, Soriano F, McNamara M, et al. Abeta deposition is associated with neuropil changes, but not with overt neuronal loss in the human amyloid precursor protein V717F (PDAPP) transgenic mouse. *J Neurosci* 1997;17:7053–7059.
183. Price DL, Sisodia SS. Mutant genes in familial Alzheimer's disease and transgenic models. *Annu Rev Neurosci* 1998;21:479–505.
184. Conrad C, Andreadis A, Trojanowski JQ, et al. Genetic evidence for the involvement of tau in progressive supranuclear palsy. *Ann Neurol* 1997;41:277–281.

Neuropsychopharmacology: The Fifth Generation of Progress. Edited by Kenneth L. Davis, Dennis Charney, Joseph T. Coyle, and Charles Nemeroff. American College of Neuropsychopharmacology © 2002.